

PROGRESSIVE DISC DEGENERATION IN THE CERVICAL SPINE FROM C6-7 TO C4-5

Here is shown progressive disc degeneration at the C4-C5 level. It is interesting from a clinical and medicolegal standpoint to observe this phenomenon. Often we are asked the time element of disc degeneration following injury or in this case following disc degeneration at a specific level of the cervical spine.

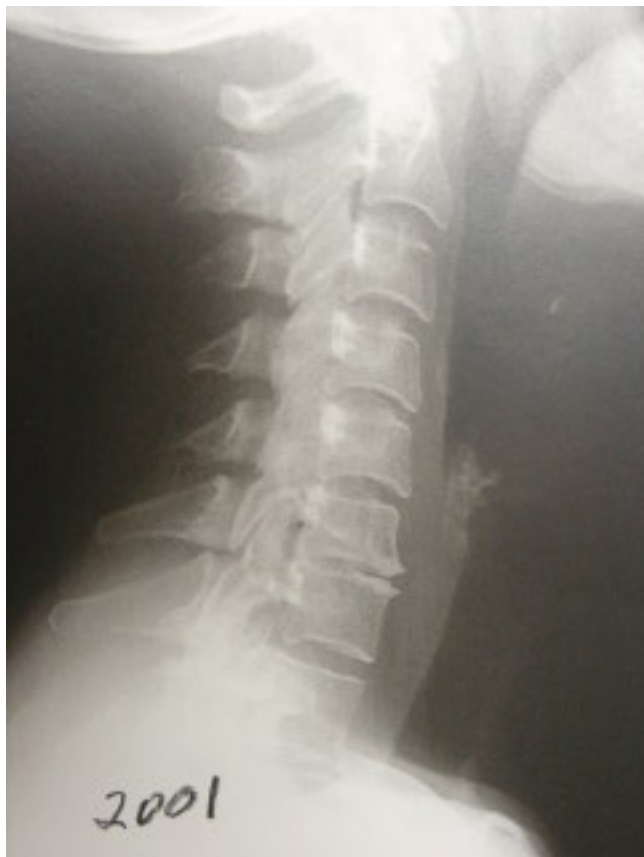

Figure 1: note the degenerative changes at the C6-7 disc level with the loss of physiological sagittal curve and flexion subluxation of C3 on C4. Note the normal appearance of the cephalad and caudad discs to C6-7, especially the C4-5 level. This x-ray was taken in 2001.

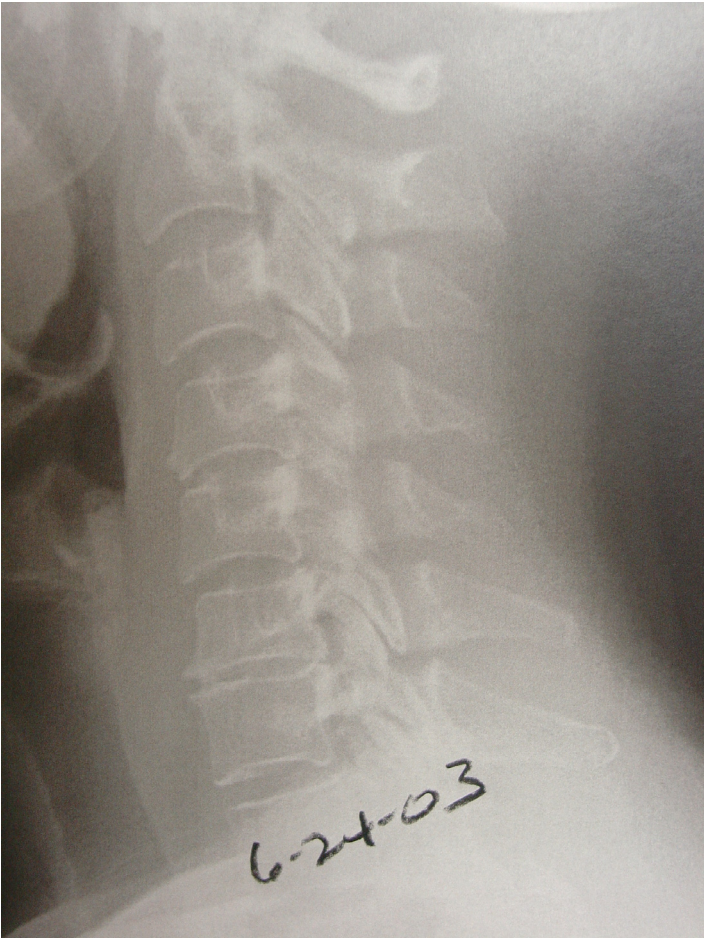

Figure 2: This film is taken two years after Figure 1. The patient now has radicular pain in the right upper extremity. The same degenerative changes are noted at the C6-7 level, but now note the anterior endplate hypertrophy at the C4-5 level and anterior slip of C5 on C6 which has developed in the previous two years, indicating instability of the C5-6 disc.

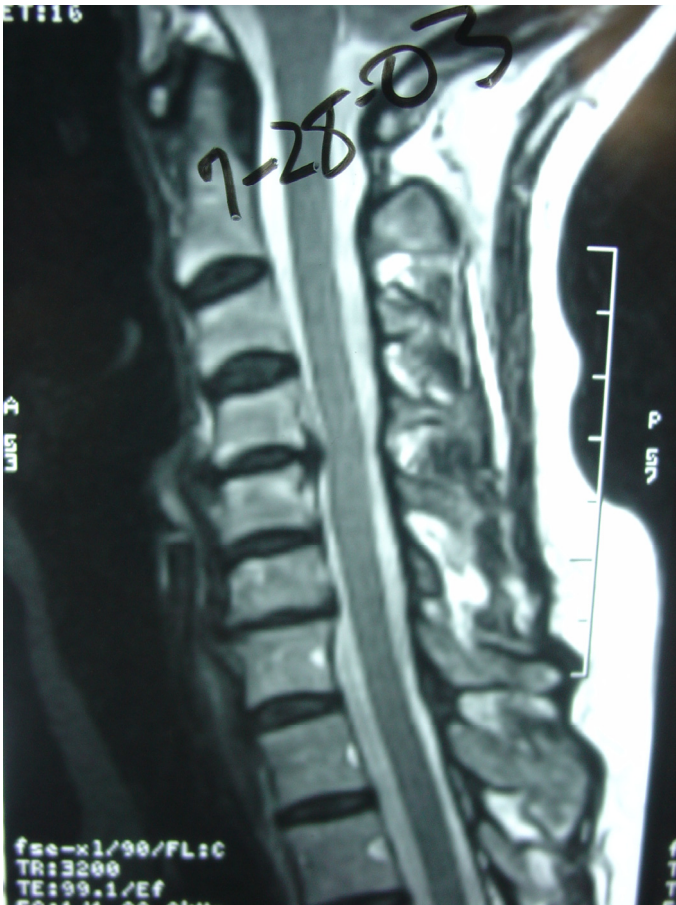

Figure 3: this MRI is ordered due to persistent right arm pain and now shows that the C4-5 disc is herniated to contact the anterior thecal sac.

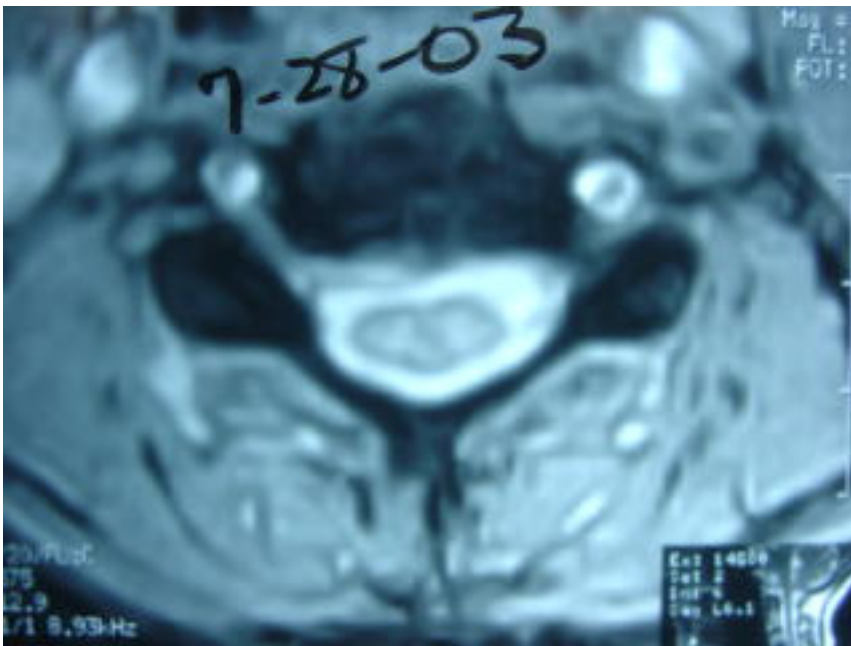


Figure 4: Note the C4-5 central and right posterior disc herniation which does not compromise the spinal cord but does create right anterior vertebral canal narrowing.

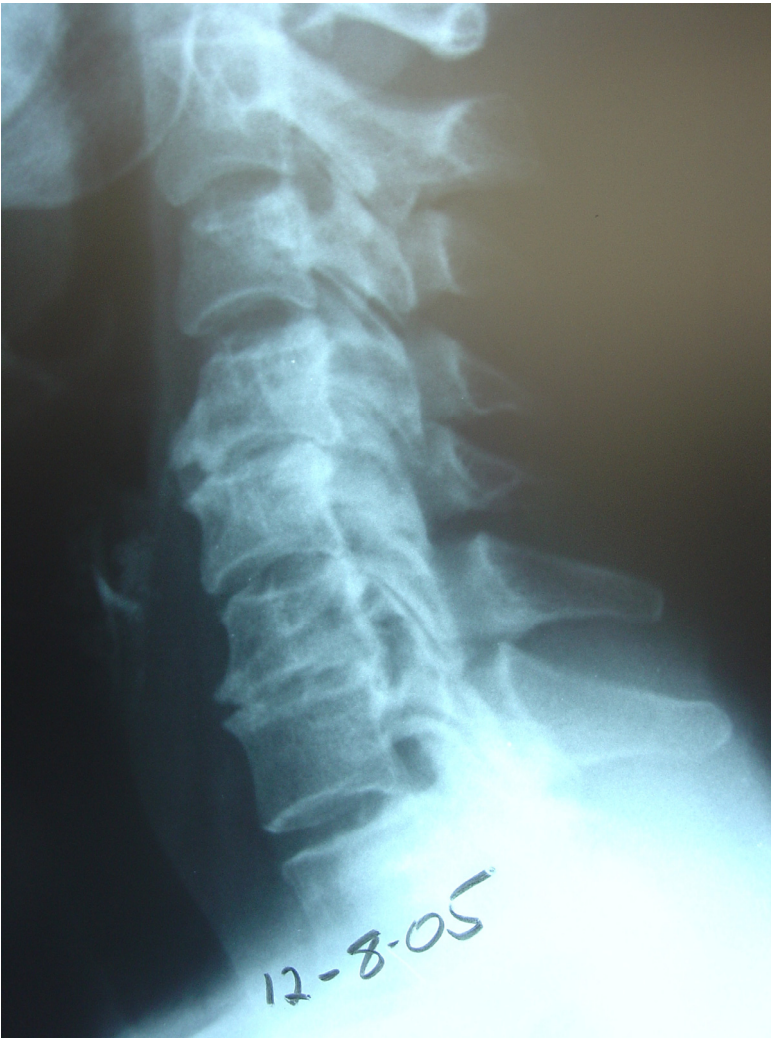

Figure 5: Now two years after the appearance of the C4-5 disc herniation, note the degeneration of the C4-5 disc with retrolisthesis subluxation. The C6-7 disc degeneration that was noted in the 2001 study, four years previous, is still present. Note the preserved C5-6 disc space.

THIS STUDY DOCUMENTS DISC HERNIATION AND DEGENERATION CEPHALWARD TO THE INITIAL C6-7 DISC DEGENERATION. IN FOUR YEARS, THE C4-5 DISC HAS HERNIATED AND DEGENERATED. INTERESTINGLY, THE C5-6 DISC SPACE IS RELATIVELY SPARED IN THIS PROCESS. IT POINTS OUT THAT THE SEGMENT DIRECTLY ABOVE THE DEGENERATED DISC MAY NOT BE THE NEXT TO BECOME UNSTABLE, HERNIATE, AND DEGENERATE. WHY IS THE C5-6 DISC SPARED AND C4-5 STRESSED TO THE POINT OF HERNIATION AND DEGENERATION?

Respectfully submitted,
James M. Cox, D.C., D.A.C.B.R.

